

# Manejo del dolor

## Effect of diamagnetic therapy to manage a patient with degenerative cervical myelopathy and drug's intolerance

# Manej

Vincenzo Rania, Gianmarco Marcianò, Cristina Vocca, Caterina Palleria, Lucia Muraca, Pietro Romeo, Felipe Torres & Luca Gallelli

To cite this article: Vincenzo Rania, Gianmarco Marcianò, Cristina Vocca, Caterina Palleria, Lucia Muraca, Pietro Romeo, Felipe Torres & Luca Gallelli (22 Jun 2025): Effect of diamagnetic therapy to manage a patient with degenerative cervical myelopathy and drug's intolerance, Pain Management, DOI: [10.1080/17581869.2025.2523729](https://doi.org/10.1080/17581869.2025.2523729)

To link to this article: <https://doi.org/10.1080/17581869.2025.2523729>



Published online: 22 Jun 2025.



Submit your article to this journal [↗](#)



View related articles [↗](#)



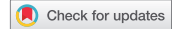View Crossmark data [↗](#)

# Efecto de


Full Terms & Conditions of access and use can be found at  
<https://www.tandfonline.com/action/journalInformation?journalCode=ipmt20>

# Paciente con

CASE REPORT



## Effect of diamagnetic therapy to manage a patient with degenerative cervical myelopathy and drug's intolerance

Vincenzo Rania<sup>a</sup>, Gianmarco Marciandò <sup>a</sup>, Cristina Vocca<sup>a</sup>, Caterina Palleria<sup>a</sup>, Lucia Muraca<sup>b</sup>, Pietro Romeo<sup>b</sup>, Felipe Torres<sup>a,b</sup> and Luca Gallelli<sup>a,b</sup>

<sup>a</sup>Operative Unit of Pharmacology and Pharmacovigilance, "Renato Dulbecco" University Hospital, Catanzaro, Italy; <sup>b</sup>Research Center FAS@UMG, Department of Health Science, University Magna Graecia, Catanzaro, Italy

### ABSTRACT

Degenerative cervical myelopathy (DCM) is a common condition among the world population, and 35.3% in the healthy population, and 35.3% in the population older than 60 years of age. It is difficult and implies chronic management. The use of drugs is important long-term consequence, but the use of prescribed drugs and with few side effects. In this case, a 44-year-old woman who was diagnosed with DCM, she did not show any signs of improvement. She declined the surgical treatment as well. Following clinical assessment, a diamagnetic pump treatment with pulsed electromagnetic fields for 3 months (once-twice weekly for 30 min, magnetic flux density 86 mt at the site of treatment) resulted in a clinical improvement. The benefits of diamagnetic therapy were three-faced including pain improvement, functional status, and imaging (magnetic resonance imaging (MRI) showing bone marrow edema reduction and myelopathy improvement). This is the first case of diamagnetic therapy in DCM, alongside

### CERVICAL PAIN MAY BE CURED ALSO WITH DIAMAGNETIC THERAPY

Cervical pain is very common worldwide and it can lead to the risk of damages to the body. Diamagnetic therapy, an alternative treatment with no drugs involved, may help patients and citizens to reduce the number of drugs consumed and to improve the signs of their illness. We describe in this article the case of a 44-year-old woman, who did not want drugs or had some issues in consuming them and was managed through the use of a local therapy based on magnetic fields (given with a kind of a plaster), that have no side effects and few reasons for whom you must not do it (for example, if you have a pacemaker, you must not do it). This therapy has the capacity to walk and do physical activities before therapy.

So, if you have cervical pain, your treatment can be completed and the number of days c

### ARTICLE HISTORY

Received 7 February 2025

### 1. Introduction

Degenerative cervical myelopathy (DCM) is a common condition among the world population, with a prevalence of 24.2% in the healthy population and 35.3% among individuals older than 60 years of age. Arthritic vertebral degeneration favors spinal cord compression in the cervical tract, leading to burning, electric shock, paresthesia, decreased strength results of the upper limbs, and spinal cord compression, are signs and symptoms of the skeletal muscle, muscular, vascular, and nervous system [1]. This clinical condition is particularly concerning considering the concomitant presence of alterations of the vertebral column (e.g., spondylarthrosis, osteophytes, bulging, and protrusions) and the involvement of the structures of peripheral and/or central nervous systems. The presence of these alterations renders

not responsive to pharmacological and non-pharmacological treatment, the quality of life could be fair and surgery could be proposed [2–4]. Among non-pharmacological treatments, the pulsed electromagnetic fields (PEMFs) also named diamagnetic

mielopatía e intolerancia a medicamentos

Vincenzo Raniaa, Gianmarco Marciandò

Felipe Torresab y Luca Gallelliab.

Unidad Operativa de Farmacología

Departamento de Ciencias de la Salud, Universidad Magna Graecia

### Article highlights

- Degenerative cervical myelopathy (DCM) is a common condition among the world population, with a prevalence of 24.2% in the healthy population and 35.3% among individuals older than 60 years of age.
- This condition affects quality of life, requires surgical treatments and is often not responsive.
- Pulsed electromagnetic fields (PEMFs) are a treatment for many musculoskeletal diseases alone or add-on to other therapies.
- We managed a 44-year-old Caucasian woman (weight 65 kg, height 170 cm, Body Mass Index (BMI) 22.49) for a 1-year history of severe neck pain and impairment in daily living. She received several pharmacological therapies with the development of side effects and without clinical efficacy. Numerical Rating Scale (NRS): 10/10.
- After 3 months, twice a week, PEMFs treatment the symptom resolved and also functional improvement in the 36-Item Short Form Survey (SF-36) questionnaire were observed ( $p < 0.01$ ).

## V. RANIA ET AL 2



their effects through the signal transduction pathway mechanism could play a role on cellular differentiation, and activity [11]. It is important to note that PEMFs exert a triple mechanism to manage pain: anti-inflammatory action reducing the production of inflammatory cytokines; anti-oedemic activity through the increase of vascular endothelial growth factor (VEGF), movement of liquids related to the diamagnetic substance movement associated to the diamagnetic effect of diamagnetism; neuromodulator and neurotrophic effect acting on several targets, including ion channels and Brain-Derived Neurotrophic Factor (BDNF) [7,12–15]. Here, we present a 44-year-old Caucasian woman with a chronic history of DCM, successfully treated with diamagnetic therapy using a diamagnetic pump (CTU MEGA 20®-Periso SA. Pazzallo-Switzerland), alongside functional improvement and good recovery of imaging findings. Diamagnetic therapy through diamagnetic pump (Figure 1) is the best choice for managing patients with DCM. In fact, PEMFs are delivered using a handpiece that has a plate at its extremity. In this way, massage therapy may be performed concomitantly to PEMFs delivery, moving the device. This allows noninvasive treatment, but also a strong effect on the interested structures.

## 2. Case presentation

A 44-year-old Caucasian woman (weight 65 kg, height 170 cm, Body Mass Index (BMI) 22.49) came to our attention with a 1-year history of severe neck pain with weakness and numbness of the upper limbs, and with a progressive impairment in daily living.

The patient had a history of gastritis, herpes zoster infection, and chronic venous insufficiency. No trauma was referred. She was treated with steroidal and non-steroidal anti-inflammatory drugs (dexamethasone, prednisolone, paracetamol, naproxen, ibuprofen) without clinical benefit. Moreover, the development of gastrointestinal adverse events (gastric pain, reflux) led to the discontinuation of the treatment. A treatment with codeine and tramadol was started with the development of stypsis and hypertension. A neurological evaluation diagnosed a DCM, and a treatment with pregabalin

## Artículos destacados



## La mielopatía cervical degenerativa

afecta a un 24,2% entre la población mundial, con una prevalencia del 35,3% entre personas mayores de 60 años de edad.

Esta condición afecta la calidad de vida de los pacientes, requiriendo tratamientos con fármacos y a menudo no respondiendo a los mismos.

Los campos electromagnéticos pulsados son un tratamiento para muchas enfermedades musculoesqueléticas y otras terapias.

Tratamos a una mujer caucásica de 44 años con dolor de cuello y deterioro de la vida diaria.

Figure 1. Diamagnetic PUMP.

Tratamos a una mujer caucásica de 44 años con dolor de cuello y deterioro de la vida diaria.

Los campos electromagnéticos pulsados son un tratamiento para muchas enfermedades musculoesqueléticas y otras terapias.

Tratamos a una mujer caucásica de 44 años con dolor de cuello y deterioro de la vida diaria.

Tratamos a una mujer caucásica de 44 años con dolor de cuello y deterioro de la vida diaria.

Tratamos a una mujer caucásica de 44 años con dolor de cuello y deterioro de la vida diaria.

Tratamos a una mujer caucásica de 44 años con dolor de cuello y deterioro de la vida diaria.

Tratamos a una mujer caucásica de 44 años con dolor de cuello y deterioro de la vida diaria.

the pain medicine  
Stanzano, Italy, for

the pain medicine Stanzano, Italy, for

**Table 1.** Short Form Health Survey (SF) 36 recorded in the enrolled patient 3 months (T1) after the admission (T0). Data are expressed as mean  $\pm$  standard deviation of three evaluations for each time. \*\* $p < 0.01$ .

	SF-36		
	T0	T1	P
Physical functioning	25.1 $\pm$ 1.2	61.3 $\pm$ 2.1**	0.000
Role limitations due to physical health	26.2 $\pm$ 2.1	62.7 $\pm$ 1.9**	0.000
Role limitations due to emotional problems	27.3 $\pm$ 1.7	63.1 $\pm$ 1.6**	0.000
Energy/fatigue	29.6 $\pm$ 1.6	67.2 $\pm$ 1.7**	0.000
Emotional well-being	28.3 $\pm$ 1.8	65.1 $\pm$ 1.2**	0.000
Social functioning	31.5 $\pm$ 1.7	70.2 $\pm$ 1.4**	0.000
Pain	23.1 $\pm$ 1.1	62.5 $\pm$ 1.6**	0.000
General health	21.9 $\pm$ 2.8	69.8 $\pm$ 2.1**	0.000
Health change	30.2 $\pm$ 1.0	76.7 $\pm$ 1.1**	0.000

sleep, mainly difficulties in falling asleep. The use of the 36-Item Short Form Health Survey (SF-36) questionnaire revealed a low quality of life [18] (Table 1).

Magnetic resonance imaging (MRI) and electromyography (EMG) were prescribed. The MRI revealed the presence of bone edema at C3-C4 with multiple compressions (Figure 2), and a chronic degenerative myelopathy at C5 (Figure 3); the EMG revealed a slight impairment of the median nerve fibers in the distal tract on the right and left for the sensory and motor component, with concurrent signs of neurogenic suffering in the brachial plexus muscles in the root of the C5 and C6 nerve on the right and left as well as in T1 on the left (modest degree).

A diagnosis of chronic degenerative myelopathy in a patient with mixed pain and drug intolerance was performed. A treatment with both l-acetyl carnitine and pregabalin was suggested but the patient refused it; therefore, a 3-month treatment (biweekly) with diamagnetic therapy was prescribed. During each session of treatment, lasting 30 min, the patient was placed in a prone position and the diamagnetic pump was positioned along the C2-C6 and a new protocol for edema/pain was applied (Table 2).

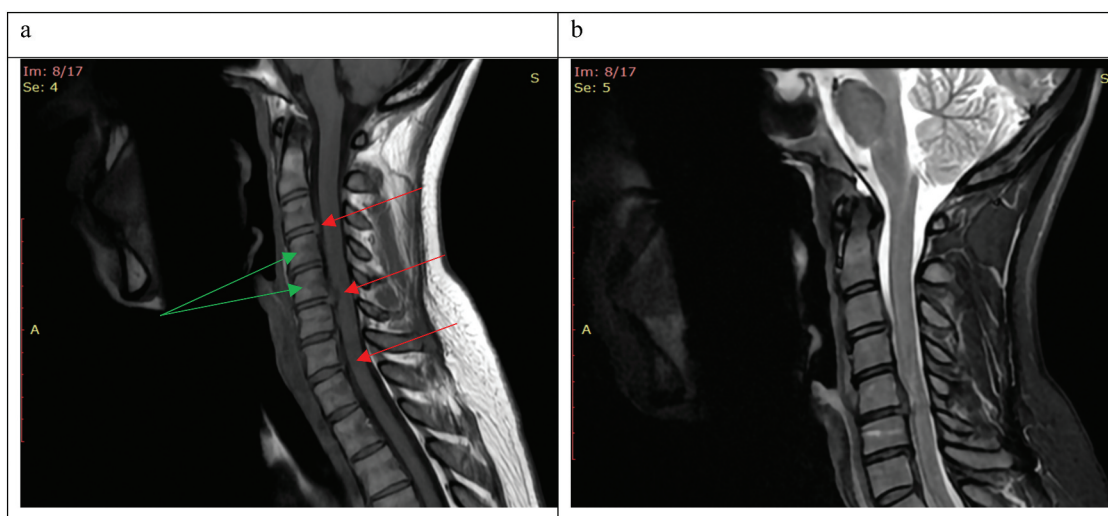
Both NRS and DN4 were evaluated before and after each session of treatment. At the time of admission (T0) and at the end of the treatment (T1: 3-month), the SF-36 questionnaire

was given. NRS and SF-36 were used as indicators of efficacy, while the occurrence of adverse events as indicators of safety.

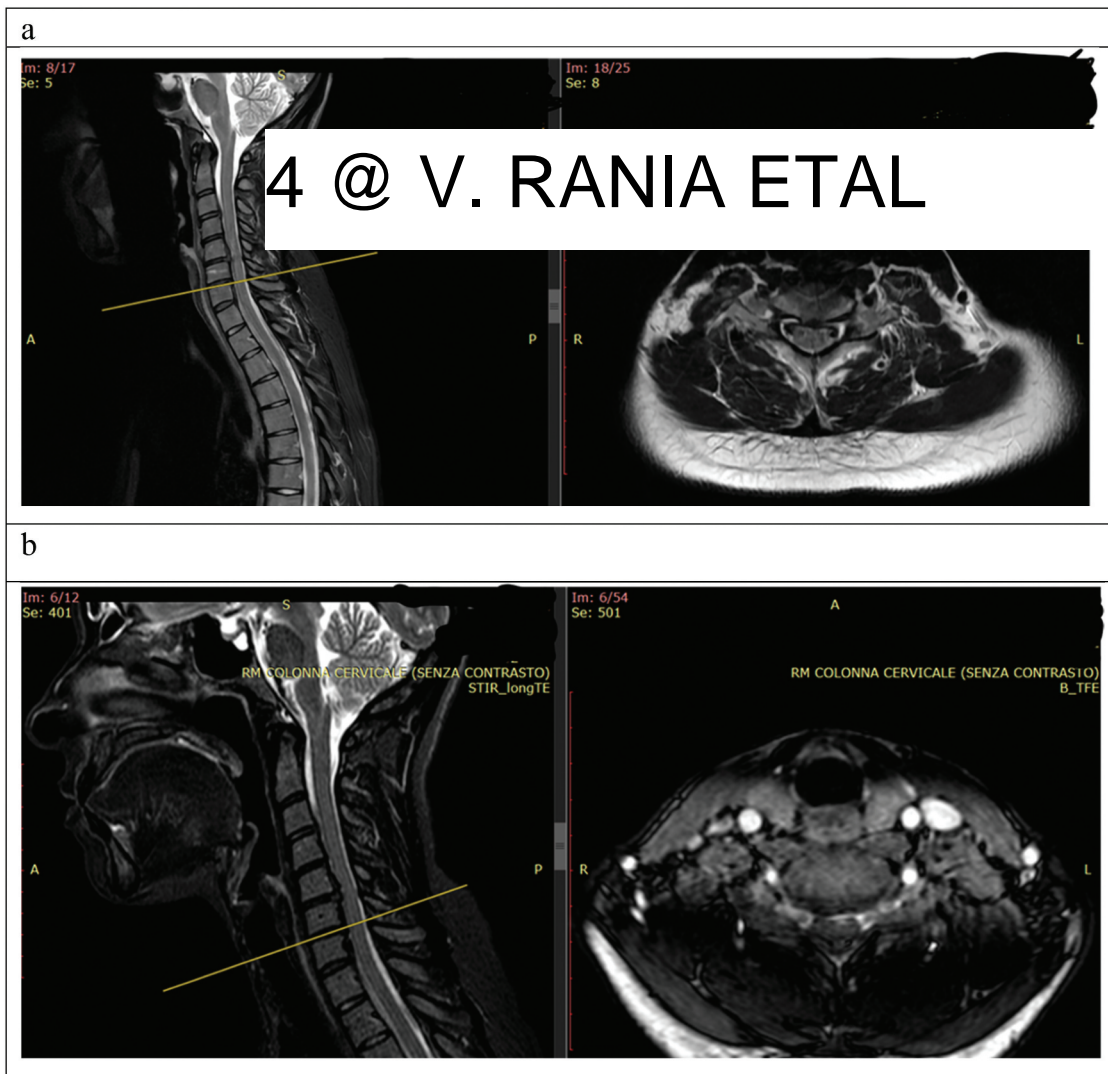
We observed a significant ( $p < 0.01$ ) decrease in pain (NRS: 2/10) and neuropathic symptoms (DN4: 3/10) at the conclusion of the treatment session (T1; week 12), along with improvements in sleep and quality of life (Table 1). Higher scores on the SF-36 questionnaire were noted for physical functioning, role restrictions brought on by emotional and physical health issues, and bodily pain as compared to baseline. Furthermore, MRI imaging improved at the end of the treatment (Figure 3), with reduction of Bone Marrow Edema and myelopathy. Over the course of the treatment, no adverse events were described by patients.

### 3. Discussion

We reported a woman with clinical symptoms related to DCM that improved after 3 months of diamagnetic therapy [19]. Previous data suggested that untreated mild myelopathy could lead to severe impairment of neurological status and severe pain [3]. In this case, our patient denied a history of injury, and probably, the development of this clinical condition is degenerative. Despite the availability of different therapeutic approaches, a large number of patients have a poor outcome, experiencing some lasting



**Figure 2.** T1 fast recovery (FR) fast spin echo (FSE) (a) T1 short TI inversion recovery (STIR) (b) magnetic resonance imaging showing the presence of multiple compressions (C2-C3, C4-C5, C6-C7) (red arrows) with the presence of bone edema in C3 and C4 (green arrows).



**Figure 3.** T1 (short T1 inversion recovery) STIR magnetic resonance imaging in enrolled patient before (a) and after (b) diamagnetic therapy. It is possible to evaluate the decrease in degenerative cervical myelopathy (DCM) in C5-C6.

**Table 2.** Diamagnetic therapy program used in the treated patient.

Program	Time
Liquids movement	8 minutes Intracellular High/Extracellular High
Endogenous Biostimulation	Nerve slow 6 minutes- Cartilage-Bone 6 minutes
Neuropathic pain	High intensity 10 minutes
Magnetic flux density was 86 mT at the site of treatment	

symptoms, chronic pain, and disability, which negatively affect the quality of life [20]. Our patient presented with severe mixed pain, inducing an impairment of the quality of life and of the sleep. Prior treatments failed due to the emergency of adverse drug reactions, while surgery decompression suggested by a specialist in neurosurgery, in agreement with the guidelines [19,21] was refused. In this patient, a non-pharmacological treatment was mandatory, and the inefficacy of previous protocols of physiotherapy suggested a different approach. In fact, diamagnetic treatment improved symptoms and quality. PEMFs move water, ion molecules and biological tissue through the water repulsive effect of diamagnetism [22]; for this reason, the biophysical stimulation carried out with high-intensity,

low-frequency PEMFs is also referred to as diamagnetic therapy.

This may have determined edema reduction also according to diamagnetic therapy anti-inflammatory activity through its action on adenosine receptors  $A_2$  and  $A_3$  (upregulation), nuclear factor kappa-light-chain-enhancer of activated B cells (NF- $\kappa$ B) inhibition [14,23–25]. Furthermore, the pro-angiogenic action improves microcirculation, reducing edema [12,13,26]. Finally, part of the clinical benefit is related to neuroprotective action and modulation of sodium, potassium, and calcium ion channels [15,27–29].

Despite the absence of a high number of studies, pulsed magnetic fields have been used to manage cervical pain as shown by Hattapoglu and colleagues [30]. They observed the

improvement of enrolled subjects concerning pain, sleep, mood, and quality of life on 64 patients with cervical disc herniation, but without reporting data about MRI.

The strengths of this case report are related to the use of a new non-pharmacological approach and to the clinical response not only from the patient's perspective, but also on imaging and on functioning. However, limitations are related to the analysis of a single patient's response and the absence of local inflammation markers measurement.

The limitations of PEMFs are several, but they are easily overcoming through patient's selection. This kind of therapy is contraindicated in patients with active cancer, pacemakers, patients with implanted metallic devices that are not compatible with MRI. It is important to note that, similarly to other pain treatments, it is not effective in all patients, particularly in those with significant structural damage or underlying altered inflammatory conditions (e.g., rheumatoid arthritis). The effect on bone marrow edema is especially in blunt trauma. However, in some cases, such as neuropathic pain, cervical pain, low back pain and a new cycle after some months, alongside pharmacologic therapy, may be required. Further studies in this and other clinical settings (despite the presence of other clinical studies) and a single case study are not necessarily spread applicability.

#### 4. Conclusion

According to this and previous studies, PEMF therapy is a safe option in the management of a patient improved in a multi-face approach: not only pain as a symptom, but also physical functioning and MRI. Further randomized controlled trials with multiple sizes are necessary to confirm the effectiveness of this treatment approach. This case report aims to investigate this topic in a broader context because of its limitations on the management of these patients.

#### Author contributions

**Vincenzo Rania** and **Gianmarco Marcolini**: Methodology, Software. **Luca Gallelli**: Data curation, writing original draft preparation. **Cristina Vocca**: Visualization. Investigation. **Caterina Palleria**: Supervision. **Lucia Muraca**: Validation. **Pietro Romeo**, **Luca Gallelli**: Reviewing and Editing.

#### Disclosure statement

The authors have no relevant affiliations or financial involvement with any organization or entity with a financial interest in the subject matter or materials discussed in this article. No employment, consultancies, honoraria, stock ownership, grants or patents received or pending, or any other financial interest. No writing assistance was utilized in the preparation of this article.

#### Funding

This paper was not funded.

#### Ethical declaration

The patient provided written informed consent with respect to the type of treatment (during the first admission) and for the publication of this case report.

#### ORCID

Gianmarco Marciàno  <http://orcid.org/0000-0003-1478-9551>

mejora de las materias matriculadas

Estado de ánimo y calidad de vida

hernia, pero sin reportar datos sobre

Los puntos fuertes de este informe

un nuevo enfoque no farmacológico

respuesta no sólo desde la perspectiva

El paciente dio su consentimiento

al análisis de la respuesta de un solo paciente

de la medición de marcadores de inflamación

Las limitaciones de los PEMF son

ORCID superación mediante

está contraindicado en pacientes

12. Premi E, Benussi A, La Gatta A, et al. Modulation of long-term potentiation-like cortical plasticity in the healthy brain with low frequency-pulsed electromagnetic fields. *BMC Neurosci.* 2018;19(1):1–6. doi: [10.1186/s12868-018-0434-z](https://doi.org/10.1186/s12868-018-0434-z)
- **Discussion about pain clinical scores to understand their reliability in clinical practice.**
13. Peng L, Fu C, Wang L, et al. The effect of pulsed electromagnetic fields on angiogenesis. *Bioelectromagnetics.* 2021;42(3):250–258. doi: [10.1002/bem.22330](https://doi.org/10.1002/bem.22330)
- **Discussion about pain clinical scores to understand their reliability in clinical practice.**
14. Varani K, Vincenzi F, Ravani A, et al. Adenosine receptors as a biological pathway for the anti-inflammatory and beneficial effects of low frequency low energy pulsed electromagnetic fields. *Mediators Inflamm.* 2017;2017:1–11. doi: [10.1155/2017/2740963](https://doi.org/10.1155/2017/2740963)
15. Urnuksaikhon E, Mishig-Ochir T, Kim SC, et al. effect of low frequency-pulsed electromagnetic field on a biological pathway for the anti-inflammatory and beneficial effects of low frequency low energy pulsed electromagnetic fields. *Appl Biochem Biotechnol.* 2017;181(4):1361–1370. doi: [10.1007/s12010-016-2289-z](https://doi.org/10.1007/s12010-016-2289-z)
- **Useful insights about degenerative cervical myelopathy.**
16. Thong ISK, Jensen MP, Miró J, et al. The validity of pain intensity measures: what do the NRS, Vas, VRS, and FPS-R measure? *Scand J Pain.* 2018;18(1):99–107. doi: [10.1515/sjpain-2018-0012](https://doi.org/10.1515/sjpain-2018-0012)
17. Bouhassira D, Attal N, Alchaar H, et al. Comparison of pain syndromes associated with nervous or somatic lesions and development of a new neuropathic pain diagnostic questionnaire (DN4). *Pain.* 2005;114(1):29–36. doi: [10.1016/j.pain.2004.12.010](https://doi.org/10.1016/j.pain.2004.12.010)
18. Apolone G, Mosconi P. The Italian SF-36 health survey. *J Clin Epidemiol.* 1998;51(11):1025–1036. doi: [10.1016/S0895-4356\(98\)00094-8](https://doi.org/10.1016/S0895-4356(98)00094-8)
19. Jannelli G, Nouri A, Molliqaj G, et al. Degenerative cervical myelopathy: review of surgical outcome predictors and need for multimodal approach. *World Neurosurg.* 2020;140:541–547. doi: [10.1016/j.wneu.2020.04.233](https://doi.org/10.1016/j.wneu.2020.04.233)
20. Hirayama Y, Mowforth OD, Davies BM, et al. Determinants of quality of life in degenerative cervical myelopathy: a review. *Br J Neurosurg.* 2023;37(1):71–81. doi: [10.1080/02688697.2021.1999390](https://doi.org/10.1080/02688697.2021.1999390)
21. Yurac R, Matamala JM, Zamorano JJ, et al. Degenerative cervical myelopathy. *Rev Med Chil.* 2022;150(3):339–352. doi: [10.4067/S0034-98872022000300339](https://doi.org/10.4067/S0034-98872022000300339)
22. Purnell MC, Butawan MBA, Bingol K, et al. Modulation of endoplasmic reticulum stress and the unfolded protein response in cancerous and noncancerous cells. *SAGE Open Med.* 2017;7(1):1–11. doi: [10.1186/s12868-018-0434-z](https://doi.org/10.1186/s12868-018-0434-z)
23. Chang K, Chang WHS. Pulsed electromagnetic fields prevent osteoporosis in human cells in culture. *J Inflamm Res.* 2015;8:59–69. doi: [10.2147/JIR.S78631](https://doi.org/10.2147/JIR.S78631)
24. Miller SL, Coughlin DG, Waldorff EI, et al. Pulsed electromagnetic field (PEMF) treatment reduces expression of genes associated with disc degeneration in human intervertebral disc cells. *Spine J.* 2016;16(6):770–776. doi: [10.1016/j.spinee.2016.01.003](https://doi.org/10.1016/j.spinee.2016.01.003)
25. Chang K, Chang WHS. Pulsed electromagnetic fields prevent osteoporosis in human cells in culture. *J Inflamm Res.* 2015;8:59–69. doi: [10.2147/JIR.S78631](https://doi.org/10.2147/JIR.S78631)

## V. RANIA ET AL.

12. Premi E, Benussi A, La Gatta A, et al.

mielopatía. *Rev Med Chil.*

Campos electromagnéticos

(1): 1–6. doi: [10.1186/s12868-018-0434-z](https://doi.org/10.1186/s12868-018-0434-z)

• **Discusión sobre las puntuaciones**

en la práctica clínica.

13. Peng L, Fu C, Wang L, et al.

campos sobre la angiogénesis

tratamiento en la resolución

• **Discusión sobre puntuaciones clínicas**

en la práctica clínica.. doi: [10.1002/bem.22330](https://doi.org/10.1002/bem.22330)

14. Varani K, Vincenzi F, Ravani A, et al.

Efectos de la degeneración del disco